

Glomus Tumor of the Upper Extremity: An Under-Recognized Cause of Pain

Dean W. Smith MD¹

1. University of Texas – Houston Department of Orthopaedic Surgery

Introduction

Glomus tumors are benign tumors most frequently found in the hand but also reported elsewhere in the upper extremity and body. Symptoms include intense focal pain and cold sensitivity, and may also include neuropathy or complex regional pain. Patients may suffer for years before the diagnosis is made. As surgical excision commonly provides complete relief of symptoms, awareness of this tumor and its presentations can prevent unnecessary delays in treatment.

Glomus tumors account for up to 5% of all soft tissue tumors of the hand, and occur mostly within or adjacent to the nail bed. Rarely, these tumors occur in the lower extremity, pelvis, spine, head and neck, and abdominal-thoracic cavity. An accurate diagnosis may not be established for many years, especially with extra-digital tumor locations. Paroxysmal pain and

hypersensitivity to temperature change or pressure are common symptoms in cases involving the digit or nailbed. Extra-digital tumors can display unusual clinical features such as sensory neuropathy and chronic regional pain. These unusual presentations can result in misdiagnosis and delay in treatment. Pain and sensitivity from glomus tumors can be so intense that patients may display dysfunctional illness behavior, major depression, or even request amputation. Once the diagnosis is made, excision of the tumor is usually curative.

Glomus Tumor

The normal glomus body is a specialized arteriovenous anastomosis located in the stratum reticulare layer of the dermis, more concentrated in the digital and subungual areas, that plays an important role in thermoregulation.¹ Glomus cell populations are characterized by Sucquet-Hoyer canals. Glomus tumors

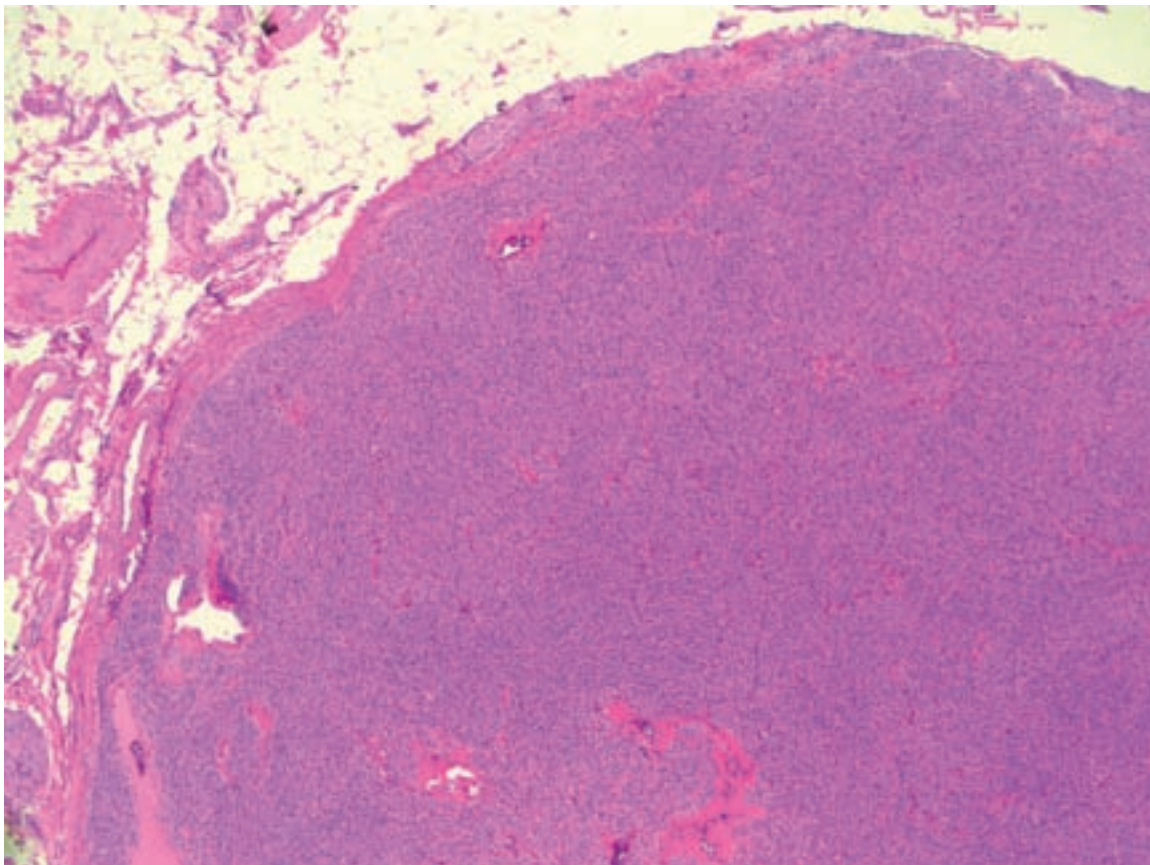


Figure. 1: Photomicrograph showing a well encapsulated nodule containing tightly packed uniform tumor cells.

are hamartomatous benign soft tissue proliferations of smooth muscle cells that typically present as small non-distinctive tumors of the distal extremities, most often within or adjacent to the nailbed. Rare instances of malignant transformation have been described, as has an association with neurofibromatosis type I.² The initiating event for glomus cell proliferation and tumor formation is unknown and can occur at any age.

An association of glomus tumor with complex regional pain syndrome has been reported in only a few cases.^{2,3,4,5} In cases involving chronic pain, patients demonstrated one or more of the following: major psychological consequences, suicidal tendencies, and/or request for amputation. Delays in diagnosis (range 4-20 years) were reported, along with complete resolution of the chronic pain after surgical removal of the tumor.

Surgical excision of the tumor is an effective treatment.^{2,6} Histopathology typically shows a well-encapsulated collection of densely packed benign uniform tumor cells surrounded by a fibrous rim that stains positive for smooth muscle actin and vimentin (Figure 1).

Clinical Findings

The characteristic symptoms of a glomus tumor, a triad of sensitivity to cold, localized tenderness, and severe intermittent pain, may not always be present, especially with extra-digital tumor locations.⁷ The pain can be excruciating, made worse with dependent posturing of the extremity. Tumors located within the nailbed or near the skin surface may demonstrate a bluish hue. Tumors located adjacent to nerves may present as sensory neuropathy.⁸ Three clinical tests have been described (the Love pin test, Hildreth test, and cold sensitivity test⁶) to assess for glomus tumor in the upper extremity: none has excellent sensitivity or specificity.

To perform the Love pin test, the examiner presses the end of a paper clip against the area of the suspected tumor. A positive result is intensification of pain. An extension to the Love test, a positive Hildreth test occurs when exsanguination of the suspected digit or limb produces resolution of the pain associated with the pin test. The cold sensitivity test seeks increased pain and sensitivity when the area in question is exposed to a cold object or spray.

The author's personal clinical experience includes 3 patients who, on initial evaluation, had chronic paroxysmal pain of such intensity that each requested digital and/or hand amputation. Work-up identified

atypical glomus tumors in all 3 cases (2 in the digital pulp and 1 at the metacarpal base) that had been symptomatic for an average of 7 years (range 5 to 9).

Van Geertruyden et al., in 51 patients with digital tumor involvement, reported that an average of 2.5 physicians were consulted before correct diagnosis was made, and that symptom duration ranged from 1 to 40 years (average 10 years).⁹ In 20 years experience with glomus tumors, Schiefer et al. found 56 extra-digital tumors, 26 of which were on the upper extremity. The average duration of symptoms was 7 years, with most patients having experienced one or more misdiagnoses.¹⁰

Imaging

Plain radiography may reveal bony erosion or an osteolytic lesion with sclerotic border, most commonly seen in lesions involving the distal phalanx. Color-duplex ultrasonography can detect glomus tumors as small as 2 mm with high sensitivity and a high negative predictive value.^{11,12,13}

Magnetic resonance imaging (MRI) may be beneficial in cases in which the diagnosis or specific location of the lesion is in question.^{14,15} T1 MRI imaging of subungual lesions demonstrates a dark, well delineated mass, while on T2-weighted images, there is a high homogeneous signal over the tumor (Figure 2).^{15,16} Post-gadolinium and fat saturation sequences may further delineate the lesion. While this magnetic resonance signal pattern can be seen with any vascular tumor, small subungual or digital lesions with this pattern are considered pathognomonic for glomus tumor.

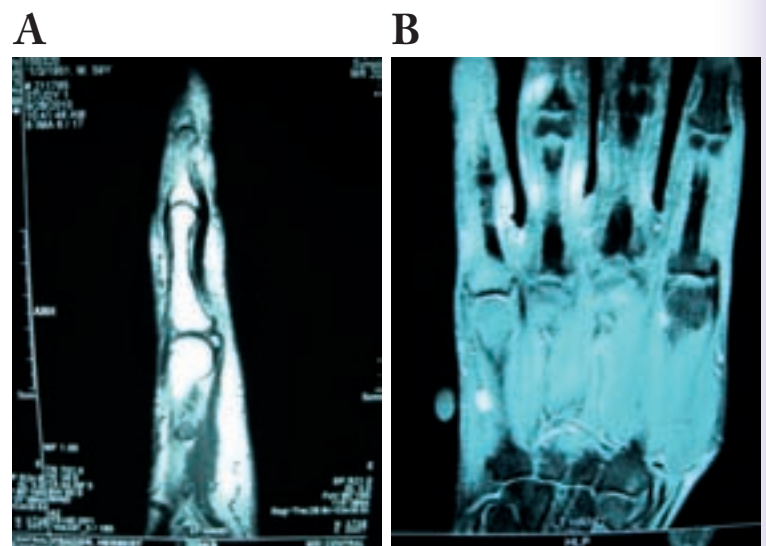


Figure 2: Magnetic resonance imaging demonstrating signal change and mass along the ulnar border of the small finger metacarpal. a. T-1 weighted image b. T-2 weighted image.

Summary

While glomus tumors are most commonly located within the subungual area of a digit, extra-digital glomus tumors occur and may present with atypical symptoms. The pain and associated sensitivity with extra-digital glomus tumors can be so intense that patients may request amputation or display major psychological effects in cases that remain untreated. Imaging studies should begin with plain radiographs and proceed to color-duplex ultrasonography or MRI as indicated. Excision of the tumor usually provides immediate pain relief.

References

1. Rettig AC, Strickland JW. Glomus tumor of the digits. *J Hand Surg.* 1977;2A(4):261-265.
2. Stewart DR, Sloan JL, Yao L, et al. Diagnosis, management, and complications of glomus tumors of the digits in neurofibromatosis type I. *J Med Genet.* 2010;47(8):525-532.
3. Longdon EJ, McCulloch TA, Perks AG, et al. Multiple glomus tumors: an unusual presentation of chronic regional pain. *Anesth Analg.* 2007;105(2):554-555.
4. Ghaly RF, Ring AM. Supraclavicular glomus tumor, a 20 year history of undiagnosed shoulder pain: a case report. *Pain.* 1999;83(2):379-382.
5. Smith DW. Periosteal glomus tumor of the metacarpal and associated type II CRPS: case report. *Hand.* 2013. in press.
6. McDermott EM, Weiss AP. Glomus tumors. *J Hand Surg.* 2006;31A(8):1397-1400.
7. Lee DW, Yang JH, Chang S, et al. Clinical and pathological characteristics of extra-digital and digital glomus tumours: a retrospective comparative study. *J Eur Acad Dermatol Venereol.* 2011;25(12):1392-1397.
8. Senol MG, Oguz M, Haholu A, et al. Glomus tumor of forearm: a rare cause of neuralgia. *Acta Neurol Belg.* 2007;107:58-59.
9. Van Geertruyden J, Lorea P, Goldschmidt D, et al. Glomus tumours of the hand. A retrospective study of 51 cases. *J Hand Surg (Br).* 1996;21(2):257-260.
10. Schiefer TK, Parker WL, Anakwenze OA, et al. Extra-digital glomus tumors: a 20 year experience. *Mayo Clin Proc.* 2006;81(10):1337-1344.
11. Matsunaga A, Ochiai T, Abe I, et al. Subungual glomus tumour: evaluation of ultrasound imaging in preoperative assessment. *Eur J Dermatol.* 2007;17(1):67-69.
12. Chen SH, Chen YL, Cheng MH, et al. The use of ultrasonography in preoperative localization of digital glomus tumors. *Plast Reconstr Surg.* 2003;112(1):115-119; discussion 120.
13. Fornage BD. Glomus tumors in the fingers: diagnosis with US. *Radiology.* 1988;167(1):183-185.
14. Theumann NH, Goettmann S, Le Viet D, et al. Recurrent glomus tumors of fingertips: MR imaging evaluation. *Radiology.* 2002;223(1):143-151.
15. Matloub HS, Muoneke VN, Prevel CD, et al. Glomus tumor imaging: use of MRI for localization of occult lesions. *J Hand Surg.* 1992;17A(3):472-475.
16. Lee S, Le H, Munk P, et al. Glomus tumour in the forearm: a case report and review of MRI findings. *JBR-BTR.* 2010;93(6):292-295.